

"THE RADIOLOGIST'S TOOLKIT: REDISCOVERING SPHERICAL OCCLUSION SURFACES"

Dr. Erika Jurate Vaitkeviciene and Dr. Andrius Kazimieras Petrauskas

Medical Scientist, Kaunas, Lithuania

Technical Sciences Specialist, Kaunas, Lithuania

ABSTRACT

This study aims to develop an algorithm for reconstructing individualized spherical occlusion surfaces from radiological DICOM data, enabling the restoration of damaged or lost structural elements in the chewing system due to various causes. Such impairments can result in severe temporomandibular joint (TMJ) disorders and psychosocial issues. Computer-aided design facilitates the precise recreation of Individualized Spherical Occlusion Surfaces using patient TMJ and upper jaw CT or CBCT data, based on consistent anatomical features. The methodology is established through the analysis of radiological data from individuals with normal occlusion, providing a foundation for oral rehabilitation. Restoring the harmony between the lower jaw and upper teeth, particularly in relation to the condyle's position in the glenoid fossa, is crucial for post-orthodontic occlusion stability and the patient's overall quality of life.

Keywords: Individualized spherical occlusion surfaces, Temporomandibular joint (TMJ), Computer-aided design, Oral rehabilitation, Glenoid fossa

Introduction

The aim of this study was to develop an algorithm to recover individualized spherical occlusion surfaces from patient radiological DICOM data and to restore structural elements of the chewing system damaged or lost due to disease, trauma, or improper prosthetics. These consequences can lead to severe lower jaw joint (TMJ) disorders (TMD) and psychosocial problems in the patient. High medical qualifications are required to restore a lost occlusal structure.

Computer-aided design allows for a sufficiently accurate reproduction of the Individualized Spherical Occlusion Surface from patient TMJ and upper jaw CT or CBCT data. Based on the intact and slightly age-varying guidelines of the solid structures of the chewing system, reliable features for the restoration of the patient's individual occlusal surface are found. This methodology was developed using radiological data from healthy individuals with normal occlusion.

Complete oral rehabilitation is the biggest challenge for every dentist in restorative dentistry. The position of the condyle is a very important factor in maintaining or restoring the harmony of the lower jaw with the upper teeth. The position of the condyle in the glenoid fossa plays an important role in the stability of the occlusion after orthodontic treatment and at the same time determines the patient's quality of life.

A key factor in the design of prosthesis and in the planning of orthognathic surgery parameters is the correct determination of the patient's occlusion: the curvature and orientation of the occlusion surface, i.e., the radius of the occlusion sphere and its center coordinates. The data from this study can be used to improve orthodontic treatment, prosthesis production, and prosthetic reconstruction outcomes. Biomechanically, the spherical occlusal surface theory is related to natural and healthy teeth [1, 2]. George Monson introduced the spherical theory of occlusion during the 1920s (ENCYCLOPAEDIA DENTALIS, Jul. 20, 1976 first Edition, Nagasue Shoten, p. 703).

His theory is based on the concept that the mandibular teeth move over the occlusal surfaces of the maxillary teeth, as over the external surface of a segment of an 8-inch sphere, and that the center of the sphere is located in the region of the Crista Galli (Starke EN. The history of articulators: A critical history of articulators based on geometric theories of mandibular movement: Part 1. Journal of Prosthodontics, Vol 11, No 2 (June), 2002: pp 134-146.).

The position of the occlusal surface of the denture wearer should be as close as possible to the spherical surface previously occupied by the patient's natural teeth. In this case, the mechanisms of the lower jaw joint with all its belonging structures, the distribution of forces and their absorption in the bone structures will function synchronously and harmoniously. Only then is the distribution of chewing forces to the support structures optimal and the dynamic stereotype of the chewing movements adequate for the patient.

The purpose of this study was to compare the restored Individual Spherical Occlusion Surface (ISOS) and the patient's Real Spherical Occlusion Surface (RSOS), to find the differences between them and to determine the impact of these differences to the joint and its diseases. During wearing this deviation can cause TMJ problems and very serious joint disorders.

Computerized image analysis and 3D modeling of bone structures allow the ISOS to be determined with sufficient accuracy, i.e. Diameter and Center coordinates. Patient image analysis and models were developed from CT or CBCT scans of the joints and upper jaw, a series of DICOM when the teeth are in maximum occlusion. Three cases with different occlusion surface positions and corresponding TMD problems are presented.

Case #1 – presents a patient with a healthy and normally functioning chewing system.

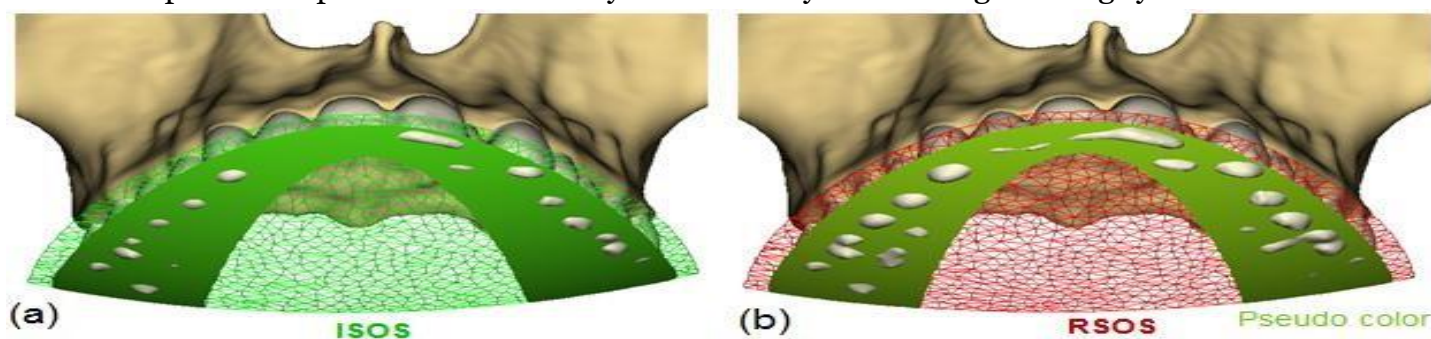


Fig.1.1 3D models of the maxillary and dental arch with spherical fragments of the occlusal surface: calculated fragment ISOS - green wire frame with occlusion region is shown in green (a); RSOS fragment (red wire frame) formed by the best-fit algorithm through occlusion contacts with pseudo

color distance deviation illustration (b). Pseudo colored distances are calculated by specifying the RSOS as the object to the ISOS as the reference (Fig.1.2 c).

The cusps should be slightly taller (a), especially when it comes to the inner ridges of the dental arch. This is concerned with bigger RSOS diameter - 260 mm, while ISOS diameter is 225 mm. A typical value of the sphere diameter according to spherical Monson's theory and concerned with the curves of Spee and Wilson is 8 inch or about 203 mm.

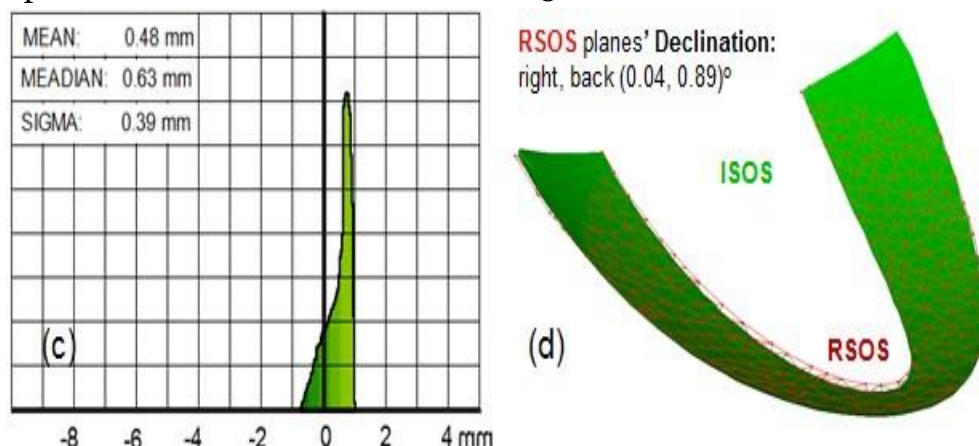


Fig.1.2 Histogram of pseudo colored distances between RSOS and ISOS occlusion regions (c). ISOS region is represented in green and RSOS region - by red wire frames (d).

Histogram is narrow (SIGMA: 0.39 mm), this means that both spheres are close and deviation is small. MEAN value +0.48 mm, this means RSOS region (red wire frame) is slightly raised according ISOS (d). Deviation is small and that is difficult to see (pseudo colored Fig. 1.1 b and Fig.1.2 d). RSOS sphere is declined to the right 0.04 ° and back 0.89 °.

The RSOS diameter is 17 % bigger than ISOS diameter; the distance between their centers is small and reaches only 19 mm.

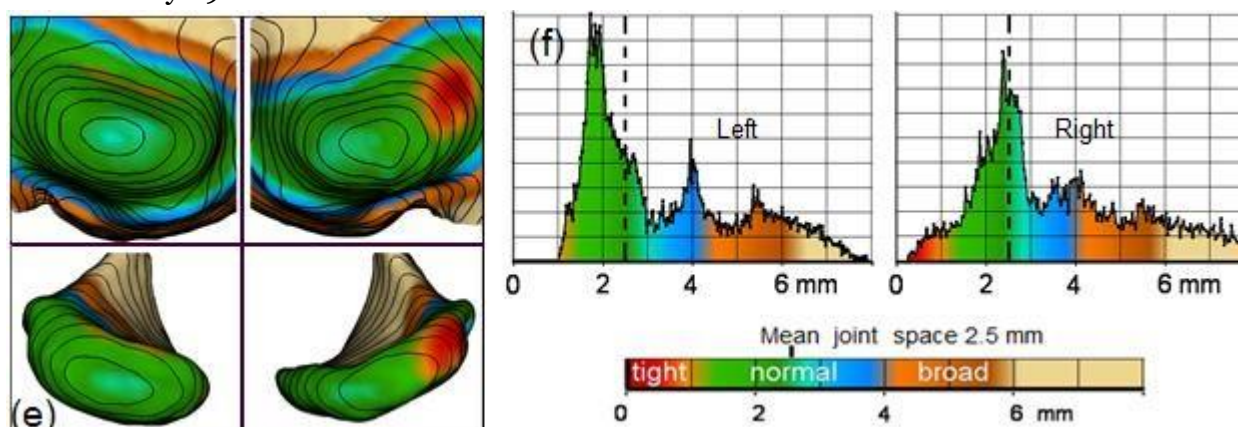


Fig.1.3 3D models with pseudo colored intra articular distances of the joints: fossae, condyles and their respective positions are shown together with 1 mm high topographic lines (e). The spacing of the joints with their histograms are illustrated by pseudo colored scales (e, f). The average spacing of a normal joint and thus the typical value of the disc thickness is 2.5 mm.

Condyles and fossil surfaces in this case are sufficiently smooth. The position of the condyles in the fossae has the small deviation - the right joint with a slight slip and a small tight space location.

Conclusion. Slight deviations from the restored Individualized Spherical Occlusive Surface were found. This means that the position of the patient's central occlusion, dental arches, and some other age-related factors have changed slightly over the time. Nevertheless, the joints are in the anatomical comfort zone and the patient shows no noticeable signs of TMJ dysfunction. The patient's occlusion is well adapted and its occlusion is functional.

Case #2 – presents a patient after trauma and improper surgery.

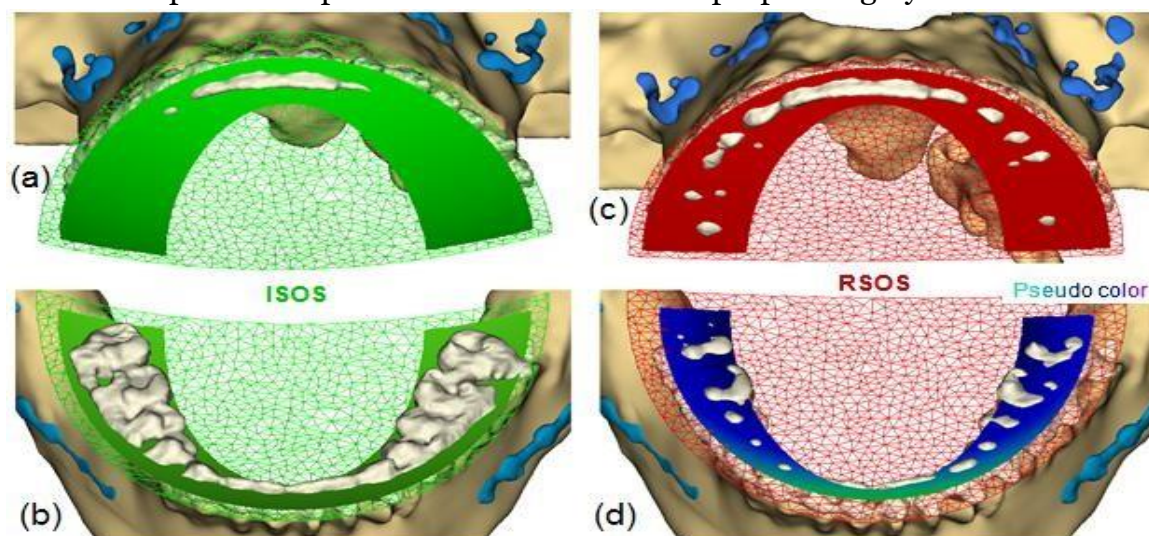


Fig. 2.1 3D models of the upper (a, c) and lower (b, d) jaws with fragments of spherical occlusal surfaces ISOS and RSOS (a, b, c) and pseudo colored distance deviation illustration (d).

The height of the anterior teeth of the lower jaw is slightly higher compared to the surface of the ISOS, but the molars of the lower jaw are 2-5 millimeters higher (b) (!).

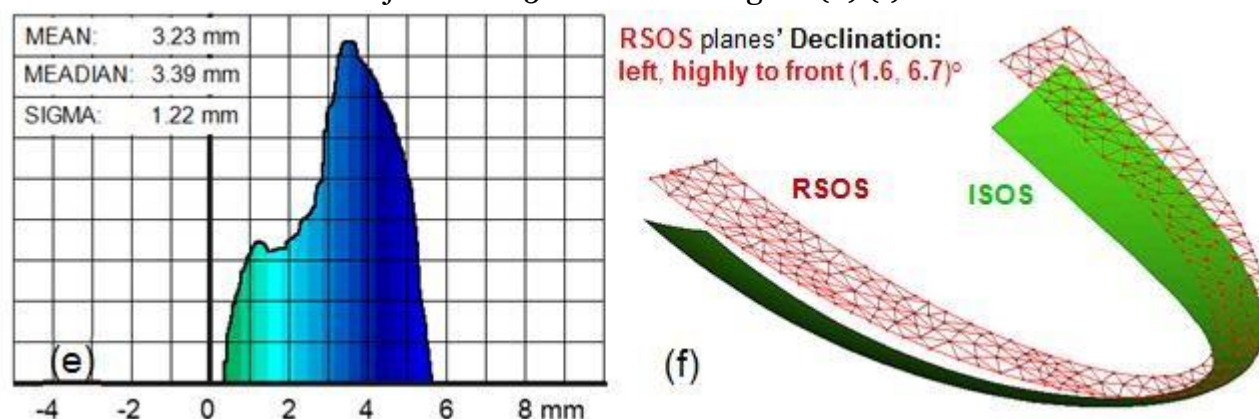


Fig. 2.2 Histogram of pseudo colored distances between RSOS and ISOS occlusion areas is colored in the same style as Fig. 2.1 d. ISOS region is represented in green and RSOS region - by red wire frames. MEAN value +3.23 mm, that means that RSOS higher than ISOS (f) and deviation huge (!). RSOS sphere is declined according ISOS to the right 1.6 ° and severely to the back 6.7 °. The histogram is very

wide (SIGMA: 1.22 mm) - this means that the occlusion planes are not parallel and significantly different: the diameter of the ISOS is 204 mm and the diameter RSOS is 956 mm, i.e. this surface is almost flat. The distance between the centers of these spheres is a huge 383 mm, so the spheres position and orientation are very different.

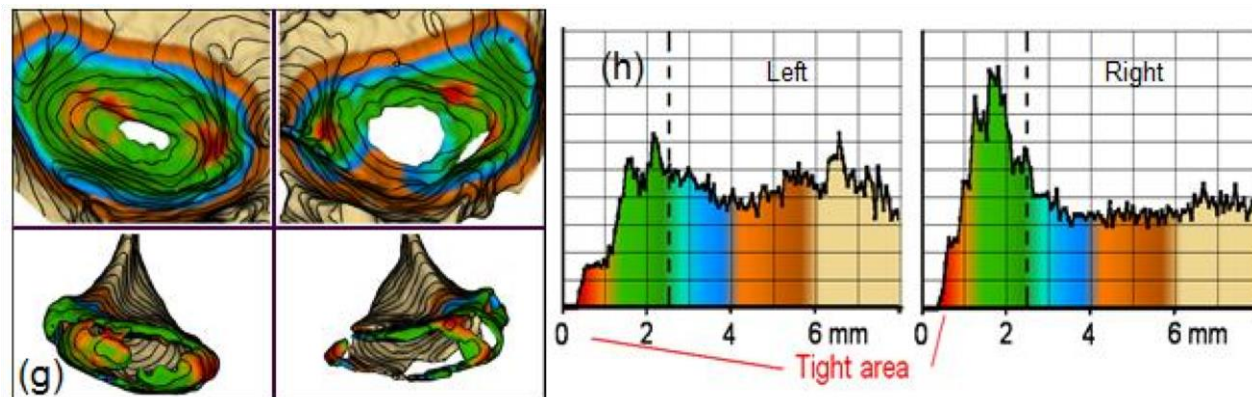


Fig. 2.3 3D models with pseudo colored intra articular distances of the joints: fossae, condyles and their respective positions are shown together with 1 mm high topographic lines (g). The spacing of the joints with their histograms are illustrated by pseudo color scales (g, h) - there are very narrow regions in both joints.

The shape and orientation of the joint fossae and condyles differed slightly (g), but hard bone of fossae and condyles was lost and perforation of the bone structure was obtained. The surfaces of the joints are very rough. The lack of sufficient mechanical support in the area of molars provoked the redistribution of chewing forces and the consequent congestion of the joints.

Improper surgical planning and surgical realization: improper occlusion plane diameter, position and orientation damaged joints and caused serious TMD. The muscles of the Temporalis, Masseter, and Pterygoideus are actively involved in the process of adapting to occlusive changes and, over the time, engage the joints discs. Overloading the disks severely impairs the occlusion function. In this case, they were overwhelmed with their duties, which led to irreversible breaches of the TMJ.

Conclusion. Incorrect diameter, position and orientation of the occlusion sphere according to restored Individualized Spherical Occlusive Surface provoked functional disc overload, resulting in perforation of the solid bone structures and significant TMJ damage.

Case # 3 - presents a patient who has lost part of his lower teeth. Over time, teeth dislocation has changed. When all of the upper teeth were lost, the removable prosthesis was fitted specifically to the remaining lower teeth.

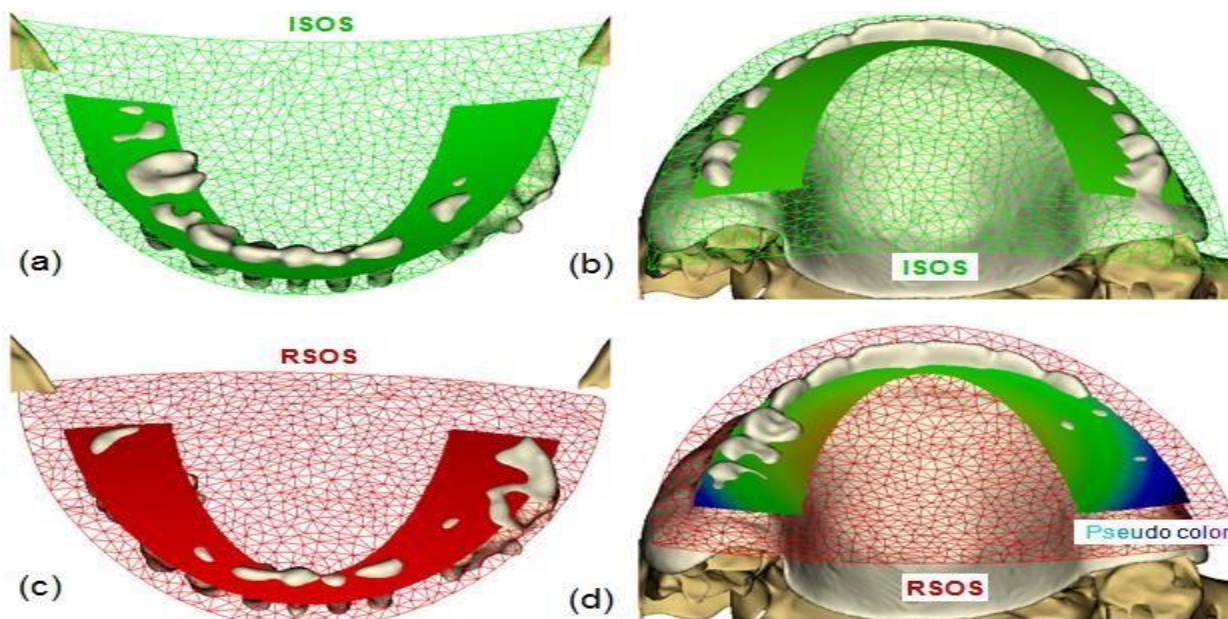


Fig. 3.1 3D models of the upper (b, d) and lower (c, d) dental arches with fragments of spherical occlusion surfaces are shown. The calculated ISOS fragment (green wire frame) is shown with green occlusion region (a, b). The RSOS fragment generated by the best-fit algorithm through the occlusion contacts is shown with a red wire frame and red region (c). The RSOS occlusion region with a pseudo color illustration of the distance deviation is shown in Fig. 3.1 d.

In the restored ISOS sphere, the internal cusps of the molars of the upper dental prosthesis should be significantly higher (b). ISOS diameter is 193 mm, very little from RSOS sphere diameter 231 mm, but RSOS sphere center is below the chin (!) and the distance between centers of these spheres is huge, even 207 mm (!) (Fig. 3.2).

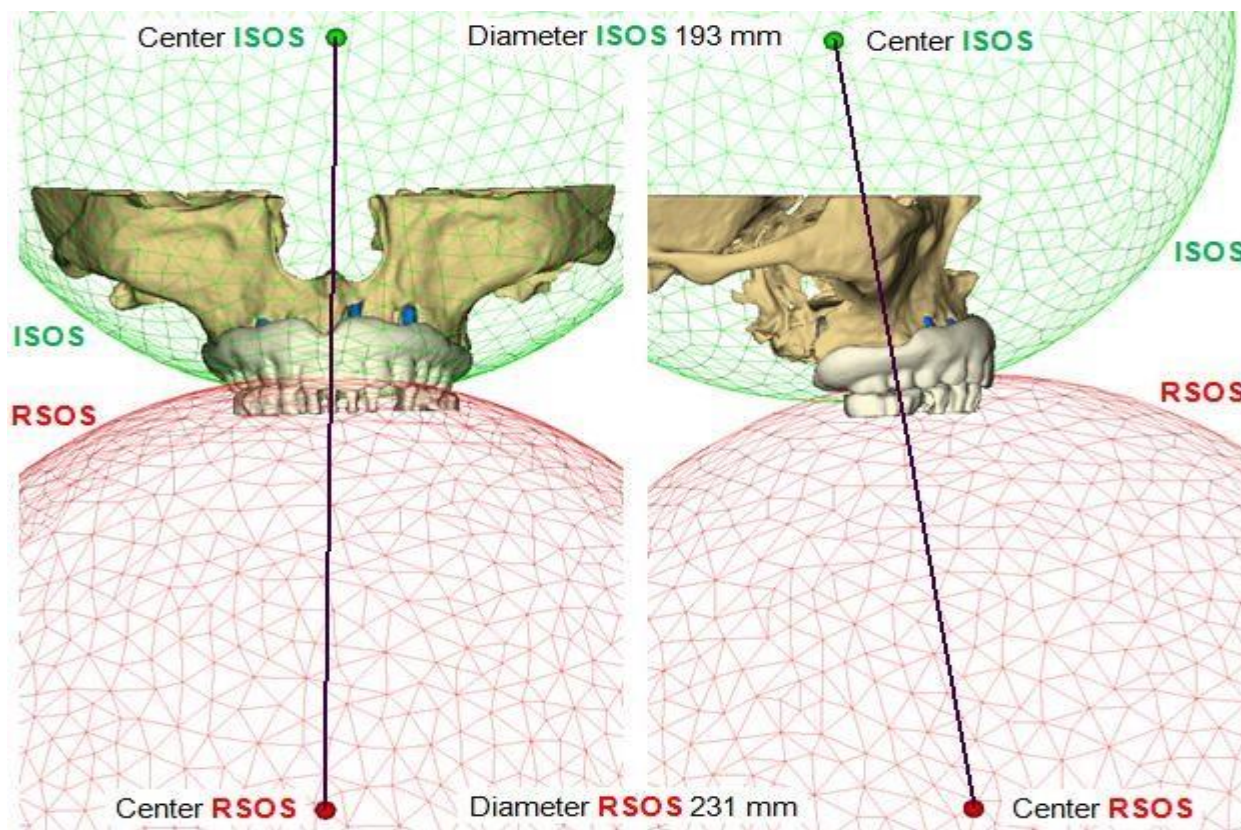


Fig. 3.2 Front and side view 3D models of maxilla, dental arches and ISOS and RSOS fragments.

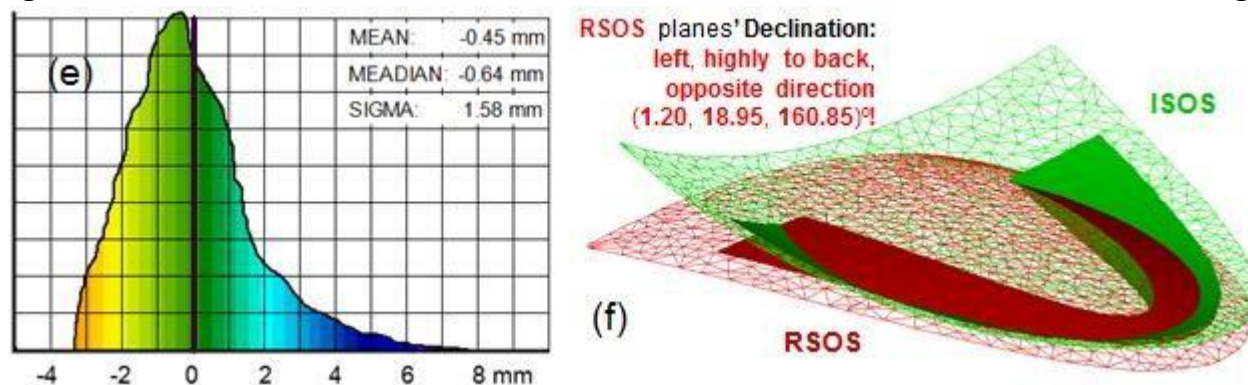


Fig. 3.3 Histogram of pseudo colored distances between ISOS and RSOS occlusion fragments (e) and ISOS region is represented in green and RSOS region - by red wire frames (f).

The histogram of the distances between the ISOS and RSOS occlusion areas, colored in the same style (Fig. 3.3 d), changed from negative values to positive values. MEAN value only -0.45 mm, but SIGMA is very wide 1.58 mm - this means that the level of the RSOS occlusion plane is more or less good, but due to the incorrect position of the RSOS center, the distances between the two occlusion regions vary over a very wide range (e, f). The occlusion sphere of the maxillary prosthesis is inversely oriented (!): RSOS declined to the left 1.2 °, highly to back 18.95 ° and opposite direction 160.85 ° (!) (Fig. 3.2).

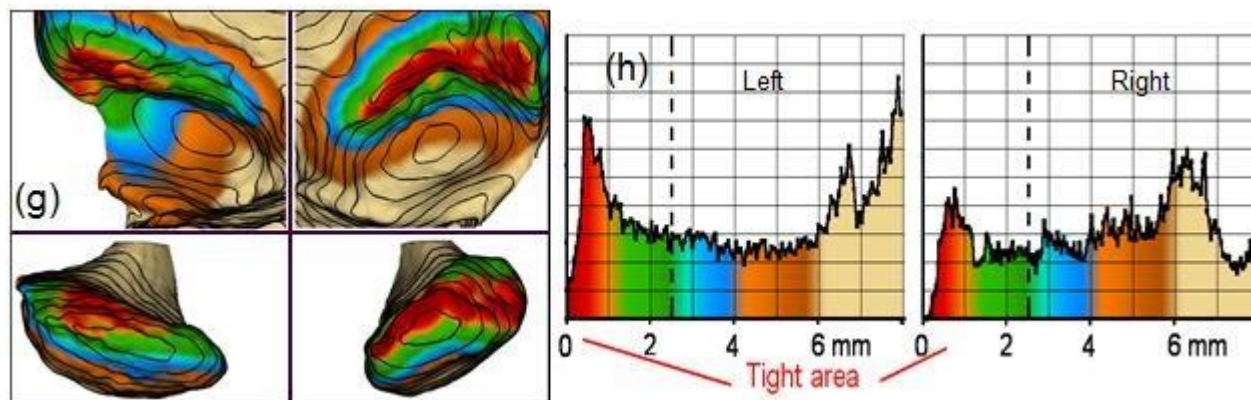


Fig. 3.4 3D models of the joints: fossae, condyles and their respective positions are depicted together with 1 mm high topographic lines (g). The spacing of the joints with their histograms are illustrated by color scales (g, h).

The shape and orientation of the joint fossae are different; the surfaces are highly rough and asymmetric. The condyles are asymmetric and the surfaces are very rough. The positions of the condyles in the fossae are very incorrect: tilted and deployed forward, asymmetric, and the gaps at the front are very narrow.

Conclusion. Improperly designed prosthesis - incorrect occlusal surface caused serious TMJ damage and at the same time serious TMD problems: headaches, problem biting, speech defects, and very serious psychological problems of the patient.

Results and discussions

Belief in and rejection of a relationship of occlusal surface and position, condyle/fossa relation and TMD are still contentious issues. Within the limitations of this study, we can conclude that from the biomechanical point of view, this data analysis shows a positive correlation.

References

Monson GS. Occlusion as applied to crown and bridgework. *Jour Nat Dental Asso* 1920; 7(5): 399–413.

Monson GS. Applied mechanics to the theory of mandibular movements. *Dent Cosmos* 1932; 4: 1039–53.